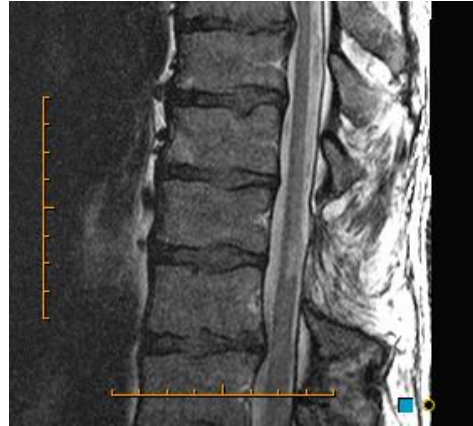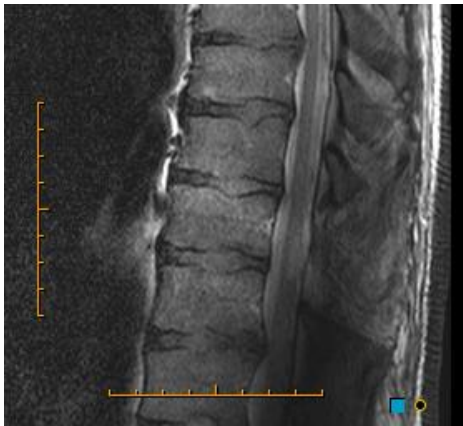


HAD ENOUGH OF 3T SPINE ARTEFACTS?

A new installation at Trinity MRI eliminates troublesome dielectric effects in the spine.

The image below left is from another institution and suffers from this phenomenon.



The Trinity MRI image on the same patient (right) shows an area of myelomalacia posteriorly within the thoracic cord adjacent to a laminectomy defect.

We also get several segments greater coverage with our new installation, reliably showing the lower cord on all examinations.

